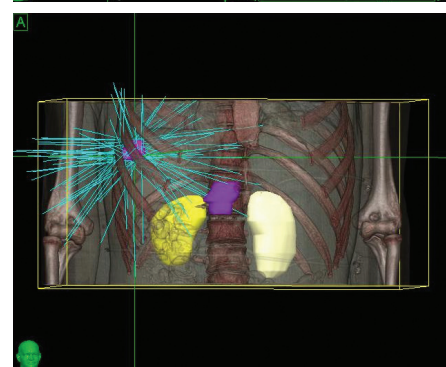
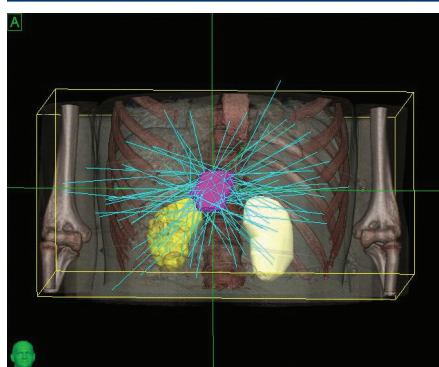
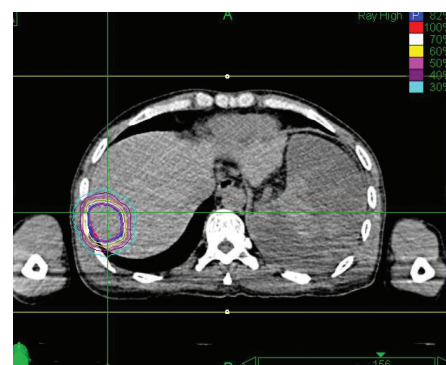
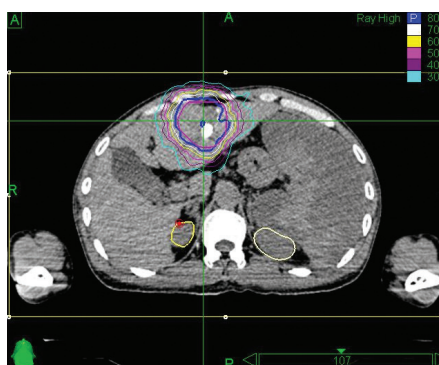

THE CYBERKNIFE® SYSTEM: BRINGING NEW HOPE FOR LIVER CANCER PATIENTS

A 42-year-old male with chronic hepatitis B was initially diagnosed with primary liver cancer. He received radiofrequency ablation. Then an MRI revealed recurrence in front of the original lesion. The patient underwent interventional therapy in March 2012, but was hospitalized a month later when a CT showed a residual tumor and acute cholecystitis. Diagnosis was hepatocellular carcinoma, T2N0M0, Stage II. The patient was treated with the CyberKnife® System at 302 Hospital of PLA.

The two identified lesions were treated with the CyberKnife System. The prescription was 48 Gy, delivered in four 12 Gy fractions for each of the two targets. Respiratory motion was managed using Synchrony® Respiratory Tracking System with fiducials. Beam-on time for each treatment was approximately 40 minutes, with a total appointment time of approximately one hour. Liver function was stable during treatment and no acute toxicity was experienced.

The initial follow-up took place four months after treatment, and CT showed no residual tumor. At the eight-month follow-up, MRI examination showed a region of necrosis in the location of the right lobe tumor. At 32 months post treatment an MRI showed no residual disease or any late toxicities.



“The CyberKnife System’s ability to track and adjust the beam with fiducials is key to giving high-dose SBRT to the liver.”

- Li Yu, M.D., Chairman, Radiation Oncology, 302 Hospital of PLA

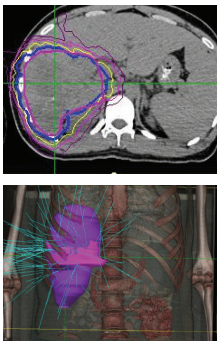
THE CYBERKNIFE® SYSTEM: EXTENDING LIFE WITH PRECISE TREATMENTS

A 24-year-old man with chronic hepatitis B presented with jaundice, poor appetite and fatty food intolerance. A CT scan showed multiple lesions in the right posterior liver, enlarged hilar lymph nodes and gall bladder invasion. Diagnosis was hepatocellular carcinoma, T3N1M0, Stage IIIC.

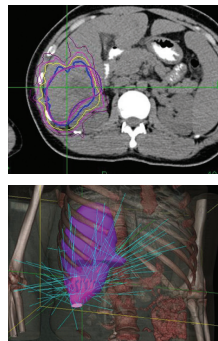
CyberKnife® treatment was delivered at 302 Hospital of PLA and implemented in two stages, with each stage covering two targets. Gold fiducial markers were implanted in the liver prior to the start of treatment.

1. Phase 1 treatment covered the right lower lobe and hilar nodes, divided into two targets. The prescription was 48 Gy, delivered in four 12 Gy fractions for each of the two targets. Bilirubin fluctuations were noted during the course of therapy, but gradually returned to normal after treatment. One month after radiotherapy, a CT scan showed tumor shrinkage. The left lobe had sufficiently enlarged in compensation, so the second stage of treatment was initiated.
2. Phase 2 treatment covered the right upper lobe, divided into two targets: The prescription was 39 Gy, delivered in three 13 Gy fractions for each of the two targets.

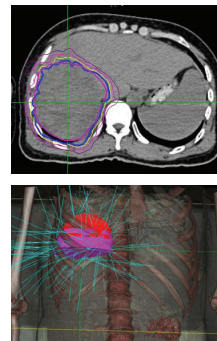
One-and-a-half months post treatment, a CT scan of the abdomen showed the tumor was shrinking. No late toxicity from the treatment was noted. At the eight-month follow-up, a CT examination showed a necrotic tumor in the right lobe.



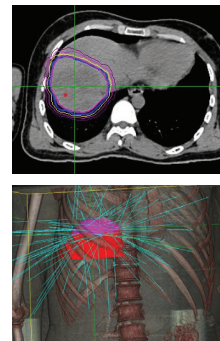
Right lower lobe target 1.



Right lower lobe target 2.



Right upper lobe target 1.



Right upper lobe target 2.

An abdomen CT showed the tumor was well controlled, although there was still some residual disease.

“The patient lived more than two years with good quality of life after initial diagnosis, when life expectancy would have been one month without CyberKnife treatment”.

– Li Yu, M.D., Chairman, Radiation Oncology, 302 Hospital of PLA

Important Safety Information:

Most side effects of radiotherapy, including radiotherapy delivered with Accuray systems, are mild and temporary, often involving fatigue, nausea, and skin irritation. Side effects can be severe, however, leading to pain, alterations in normal body functions (for example, urinary or salivary function), deterioration of quality of life, permanent injury, and even death. Side effects can occur during or shortly after radiation treatment or in the months and years following radiation. The nature and severity of side effects depend on many factors, including the size and location of the treated tumor, the treatment technique (for example, the radiation dose), and the patient's general medical condition, to name a few. For more details about the side effects of your radiation therapy, and to see if treatment with an Accuray product is right for you, ask your doctor. Accuray Incorporated as a medical device manufacturer cannot and does not recommend specific treatment approaches. Individual results may vary.

© 2022 Accuray Incorporated. All Rights Reserved. Accuray, the Accuray logo, and other trademarks are trademarks or registered trademarks of Accuray Incorporated and may not be used without permission. For more information on Accuray and its trademarks, please visit www.accuray.com/trademarks. MKT000609(2)

CyberKnife®